



Clinical Studies

Association between fatty infiltration of paraspinal muscle, sagittal spinopelvic alignment and stenosis grade in patients with degenerative lumbar spinal stenosis

Yuancheng Zhang^{a,b,c,1}, Filippo Mandelli^{a,b,c,d,e,1}, Annegret Mündermann^{a,b,c,e}, Corina Nüesch^{a,b,c,e}, Balázs Kovacs^f, Stefan Schären^{a,b,c,2}, Cordula Netzer^{a,b,c,2,*}

^a Department of Spine Surgery, University Hospital Basel, Basel, Switzerland

^b Department of Biomedical Engineering, University of Basel, Basel, Switzerland

^c Department of Clinical Research, University of Basel, Basel, Switzerland

^d Department of Orthopaedics, University Children's Hospital Basel, Basel, Switzerland

^e Department of Orthopaedics and Traumatology, University Hospital Basel, Basel, Switzerland

^f Department of Radiology, University Hospital Basel, Basel, Switzerland



ARTICLE INFO

Keywords:

Lumbar spinal stenosis
Paraspinal muscles
Fatty infiltration
Sagittal alignment
Pelvic incidence
Lumbar lordosis

ABSTRACT

Introduction: Sagittal balance and fatty infiltration of paraspinal muscle are important factors in patients with lumbar spinal stenosis (LSS) that may affect patients' quality of life. Sagittal spinopelvic parameters and fatty infiltration may be associated with the severity of LSS. The purpose of this study was to test the hypothesis that severity of fatty infiltration correlates with severity of LSS and with sagittal pelvic alignment independent of age.

Methods: Age and body mass index (BMI) were extracted. Fatty infiltration was rated according to Goutallier classification and the severity of LSS was graded according to Schizas at five intervertebral disc levels. Overall fatty infiltration was computed as average fatty infiltration (aFI) and severity of LSS was defined as the highest severity of LSS of all segments. The sagittal spinopelvic parameters pelvic incidence (PI), pelvic tilt (PT), sacral slope (SS), lumbar lordosis (LL) and PI-LL were measured. Associations among parameters were assessed using Spearman correlation coefficients adjusted for age ($\alpha = 0.05$).

Results: 165 LSS patients with a median age of 69 years were included. All parameters correlated with age ($R > 0.162$, $P < 0.05$) except BMI and LL ($R < 0.007$, $P > 0.05$). aFI correlated with PI, PT and PI-LL before ($R > 0.371$, $P < 0.05$) and after ($R > 0.180$, $P < 0.05$) adjusting for age. Severity of LSS correlated with PI, PT and PI-LL before ($R > 0.187$, $P < 0.05$) but not after ($R < 0.130$, $P > 0.05$) adjusting for age. aFI correlated with severity of LSS before ($R = 0.349$, $P < 0.05$) but not ($R = 0.114$, $P > 0.05$) after adjusting for age.

Conclusions: The correlation of aFI with sagittal spinopelvic parameters indicates that there might be a relationship between muscle characteristics and the sagittal alignment. Sagittal spinopelvic parameters and fatty infiltration of paraspinal muscles are not associated with radiological severity of LSS. Whether they are associated with clinical manifestation of LSS remains to be investigated.

Introduction

Lumbar spinal stenosis (LSS) is one of the most common diseases of the spine and the most common reason for spine surgery in patients aged over 65 years [1]. Age associated changes of the intervertebral discs, ligamentum flavum and facet joints can lead to a narrowing of the space around the neural structures causing pain, impairment and spinal

disorders [2]. Previous studies reported that paraspinal muscle atrophy and fatty infiltration were more serious in patients with symptomatic LSS than in an asymptomatic control group [3,4]. Moreover, Bumann et al. [5] reported that patients with a lower radiological stenosis grade had greater fatty infiltration. Hence, to date evidence for the association between radiological severity of LSS and fatty infiltration of paraspinal muscles is still controversial.

* Corresponding author at: Department of Spine Surgery, University Hospital Basel, Spitalstrasse 21, 4031 Basel, Switzerland.
E-mail addresses: zhangyuancheng2012@163.com (Y. Zhang), cordula.netzer@usb.ch (C. Netzer).

¹ Authors share first authorship.

² Authors share last authorship.

Patients with LSS may exhibit varying severity of sagittal malalignment by adopting an anterior trunk flexion position to relieve nerve compression by increasing the volume of the central spinal canal and intervertebral foramen [6]. Furthermore, degenerative changes in the lumbar spine are related to deterioration of the normal sagittal and coronal profile [6]. Duval-Beaupère et al. were the first to introduce the parameter of pelvic incidence (PI), its relation to pelvic tilt (PT), sacral slope (SS) and lumbar lordosis (LL), as well as its influence on the spinal alignment [7]. Spinopelvic parameters play an important role in the pathogenesis of spinal disorders and quality of life in pediatric and adult populations. Barón et al. [8] showed that PI has a predisposing role in the pathogenesis of lumbar degenerative disease and that patients with spinal stenosis have a lower PI with flatter LL. To date, the association between these parameters and severity of LSS has not been investigated.

Legaye et al. [9] demonstrated a strong positive correlation between PI and the age of subjects over 60 years. Previous studies described degeneration of paravertebral muscles in patients with spinal disease [10,11]. Possibly fatty infiltration of paraspinal muscles correlates with spinopelvic parameters of sagittal alignment. Jun et al. [12] suggested that the quality of muscle could be one of the various factors that influences sagittal balance. Masaki et al. [13] investigated the association between the mass of different muscles along the spine with different spinopelvic parameters. They found that a decrease in pelvic anterior inclination is associated with a decrease in the mass of the psoas major muscle. The relationship between fatty infiltration, severity of LSS and sagittal spinopelvic parameters have rarely been examined directly.

Based on the existing literature and our clinical observations, the following research questions arise: Is the severity of fatty infiltration of the paraspinal muscles related to sagittal spinopelvic alignment in patients with degenerative LSS? Is the degree of fatty infiltration of the paraspinal muscles related to the severity of stenosis in patients with degenerative LSS?

The purpose of this study was to test the hypothesis that the grade of fatty infiltration correlates with the severity of LSS and with sagittal spinopelvic alignment independent of age.

Materials and methods

Study cohort

This retrospective cross-sectional radiographic study was approved by the regional ethics committee and performed in accordance to the guidelines specified in the Declaration of Helsinki. We retrospectively included all patients with symptomatic degenerative LSS who had received surgery at our clinic between May 2018 and May 2020. Inclusion criteria were: diagnosis of degenerative LSS; upright standing sagittal plane X-ray of lumbar spine with clear visibility of pelvis, sacrum and femoral heads taken within 16 weeks before surgery; magnetic resonance imaging (MRI) of the lumbar region taken within 16 weeks before surgery. Exclusion criteria were: other spinal diseases such as severe scoliosis, spine fracture, and ankylosing spondylitis; neuromuscular diseases such as Parkinson’s disease or multiple sclerosis; previous surgery of the spine; infection and/or malignancy tumor with involvement of the bony or soft tissue structures of the spine; dissent for future use of medical data. General consent was presented for LSS patients who received surgery. This retrospective study on coded data was exempt by the regional ethics board from seeking informed consent from patients without general consent or dissent.

Data collection and radiographic measurement

Demographic information including age, sex and BMI (body mass index) were extracted from patient files. Standard clinical MR images with T2-weighted were acquired. The patients were in supine position with extended legs. MRI of the lumbar region was acquired. Images at mid

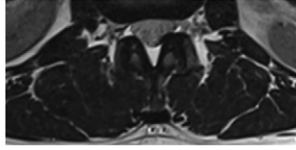
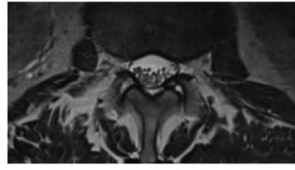
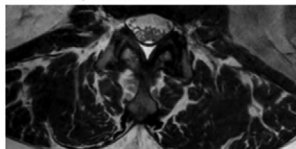
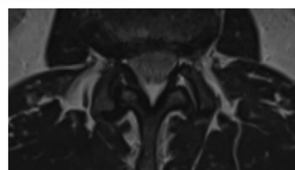
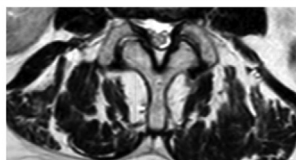
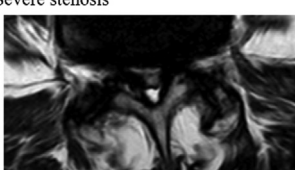
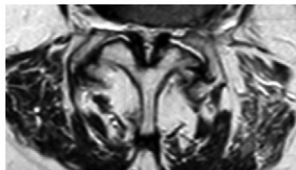
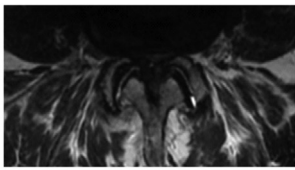
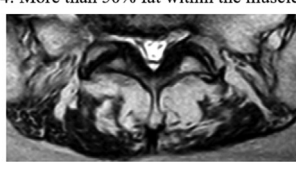
Muscle fatty infiltration classification	Stenosis grade classification
0: No fatty infiltration 	A: Dural sac partly occupied by the rootlets; Cerebrospinal fluid clearly visible; No stenosis 
1: Few fatty streaks within the muscle 	B: Rootlets occupy whole dural sac; Some cerebrospinal fluid visible; Moderate stenosis 
2: Less than 50% fat within the muscle 	C: Rootlets not visible; No cerebrospinal fluid visible; Epidural fat posteriorly; Severe stenosis 
3: 50% of fat within the muscle 	D: Rootlets not visible; No cerebrospinal fluid; No epidural fat; Extreme stenosis 
4: More than 50% fat within the muscle 	

Fig. 1. MRI examples of fatty infiltration of paraspinal muscles [14] and lumbar spinal stenosis [15] classifications.

segment of each non-stenosis intervertebral disc and images at the most severely affected part of each stenosis intervertebral disc (five images per patient) were identified, saved and further evaluated. Fatty infiltration in the paraspinal muscles erector spinae and multifidus was classified according to Goutallier into four grades from 0 to 4 [14]. Severity of LSS was graded according to Schizas into four grades (A to D) according to the occupied rootlets and visible cerebrospinal fluid [15] (Fig. 1). Grade A to D were transformed to 1 to 4 for the statistical analysis.

The paraspinal muscle group is a 3-dimensional structure composed of several muscles, and all paraspinal muscles act together to maintain balance and facilitate movement. Moreover, PI represents the anatomical morphology of the pelvis, and LL reflects the magnitude of lordosis from L1 to S1. The evaluation of a single muscle or one segment alone cannot represent the entire paraspinal muscle or the entire spine. In our study, we used the Goutallier classification [14] that is based on the area of fatty infiltration to evaluate the muscle atrophy at different levels. We measured fatty infiltration of paraspinal muscles at five vertebra disc levels and calculated the average of five levels representing overall fatty infiltration (average fatty infiltration—aFI). This parameter was used based on the assumption that fatty infiltration on one level will affect the contractile capacity of the entire muscle and can be deemed a surrogate for overall fatty infiltration of paraspinal muscles.

Overall severity of LSS was defined as the highest severity of LSS at any segment.

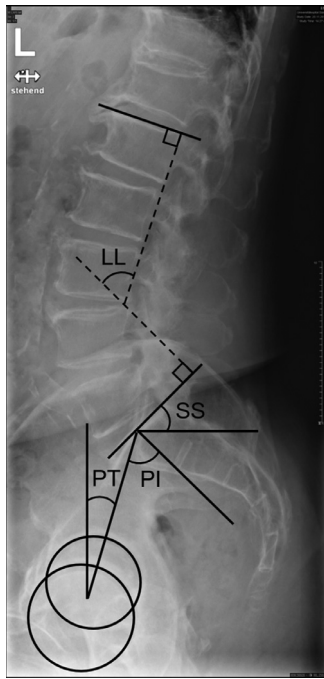


Fig. 2. Measurements of sagittal spinopelvic parameters. Pelvic incidence (PI): The angle between the line perpendicular to the sacral endplate at its midpoint and a line connecting this point to the axis of the femoral head. Pelvic tilt (PT): The angle formed by a vertical line through the center of the femoral heads and the line from the center of the femoral axis and the midpoint of the sacral end plate. Sacral slope (SS): The angle formed between the horizontal and the sacral end plate. Lumbar lordosis (LL): The angle formed between the superior end plate of L1 and the sacral end plate.

From upright standing sagittal plane X-ray of the lumbar spine, the sagittal spinopelvic parameters PI, PT, SS, LL and PI and LL mismatch (PI-LL) were measured [16]. (Fig 2).

Data quality assessment

All measurements were performed using the picture archiving and communication system (PACS). All images were first measured by a trained spine surgeon (YZ). Two weeks later, 50 patients were randomly selected, and their images were re-measured by the same reader for assessing intra-observer repeatability. Moreover, all images were independently measured by an experienced radiologist (BK). The disagreements of the results of ordinal variables (fatty infiltration stages and LSS grades) between both readers were resolved by a third reader (CNe). The inter-observer agreement of the results of continuous parameters (spinopelvic parameters) between both readers was assessed.

Statistical analysis

Descriptive statistics was performed for patients' demographics expressed as median and range. For continuous data (aFI and sagittal alignment parameters) mean and standard deviation (SD) were calculated. Intra- and inter-observer reliability analyses were performed using intraclass correlation coefficients (ICC) and limits of agreement. Bland-Altman plots were used to present the mean differences and 95% limits of agreement of repeated measurements of aFI stage and sagittal alignment parameters. Spearman coefficients of correlation were calculated to assess the relationships between aFI, severity of LSS and sagittal alignment parameters, and the association of any of these parameters with age. In case of significant association with age as suggested by Kalichmann et al. [17], Spearman coefficients of correlation

Table 1

Intraclass correlation coefficients for intra- and inter-observer repeatability of parameters describing spinopelvic alignment.

	Intra-observer ICC	Inter-observer ICC
PI	0.976 (0.959-0.987)	0.970 (0.960-0.978)
PT	0.985 (0.974-0.992)	0.966 (0.955-0.975)
SS	0.987 (0.977-0.993)	0.924 (0.898-0.944)
LL	0.990 (0.983-0.994)	0.992 (0.989-0.994)
PI-LL	0.984 (0.973-0.991)	0.971 (0.961-0.978)

Values are given as the reliability with the 95% confidence interval in parentheses. ICC—intraclass correlation coefficient; PI—pelvic incidence; PT—pelvic tilt; SS—sacral slope; LL—lumbar lordosis; PI-LL—difference between PI and LL (pelvic incidence and lumbar lordosis mismatch).

were adjusted for the covariate age. Strength of correlation were categorized as weak ($0.10 < R < 0.29$), moderate ($0.30 < R < 0.49$) and strong ($0.50 < R < 1.00$) [18]. Statistical analyses were performed in SPSS Statistics v 20.0 (IBM Corp, Armonk, New York, USA). The significance level for all statistical tests was set a priori to $P < 0.05$.

Results

Demographic data

A total of 165 patients with a median age of 69 (range: 42–86) years were included. The proportion of male patients was 44.8% (74 of 165 patients). The median BMI of all patients was 27 (range: 16–52) kg/m^2 .

Fatty infiltration

The mean of the aFI of all patients was 1.48 (SD: 0.60). The number of patients with fatty infiltration stage 0 and 1 was highest in the proximal segments (Fig. 3). In contrast, the number of patients with fatty infiltration stage 2 and 3 were highest in the distal segments. Fatty infiltration stage 4 was only observed in 15 patients, most of these at segment L5-S1 (Fig. 3).

Stenosis

The highest severity of LSS was grade A in 18 patients, grade B in 48 patients, grade C in 67 patients, and grade D in 32 patients. The number of patients with LSS grade A was highest in the most proximal and most distal segments (Fig. 3). The numbers of patients with LSS grade C and D was highest at L4-5. The number of patients with LSS grade B was comparable for all segments (Fig. 3).

Spinopelvic alignment

On average, patients had a PI of 57.4° (SD: 9.6°), PT of 21.0° (SD: 8.0°), SS of 36.4° (SD: 7.8°), LL of 47.5° (SD: 12.0°) and PI-LL of 9.9° (SD: 11.5°). The test-retest reliability was excellent for all spinopelvic parameters ($\text{ICC} > 0.976$; Table 1). Bland-Altman plots for all spinopelvic parameters revealed no bias between test and retest measurements and limits of agreement $< 4.5^\circ$ (Fig. 4). The inter-observer agreement was excellent for all spinopelvic parameters ($\text{ICC} > 0.924$) (Table 1).

Association of fatty infiltration of paraspinal muscles, grade of stenosis and pelvic alignment

There was a strong correlation between aFI and age ($R = 0.602$, $P < 0.001$). There were moderate correlations between severity of LSS ($R = 0.445$, $P < 0.001$), PI ($R = 0.472$, $P < 0.001$), PT ($R = 0.424$, $P < 0.001$), and PI-LL ($R = 0.397$, $P < 0.001$) and age. The correlation between SS

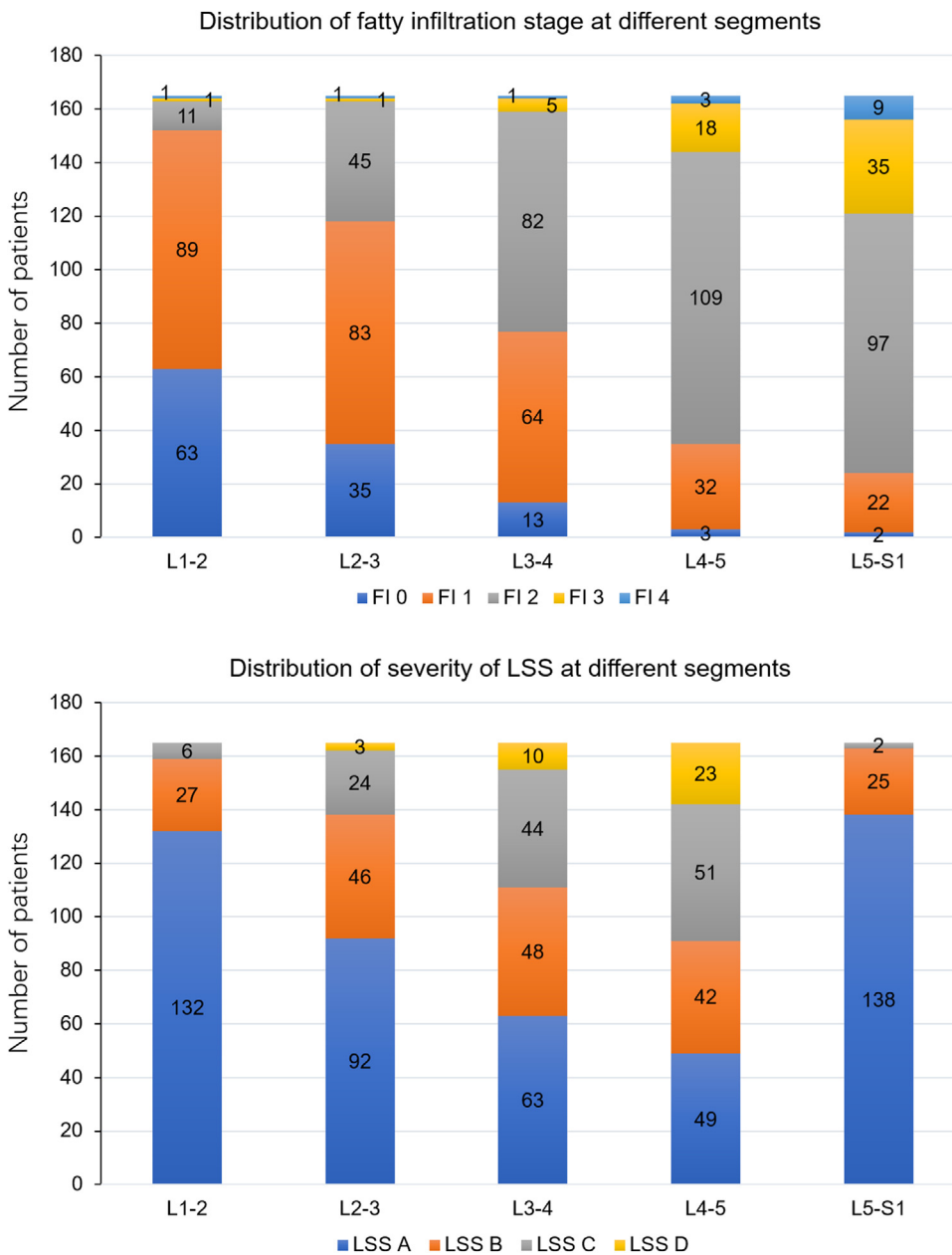


Fig. 3. Distribution of fatty infiltration of paraspinal muscles (FI) and severity of lumbar spinal stenosis (LSS) at each level.

and age was weak ($R=0.162$, $P=0.038$). LL did not correlate with age ($R=0.001$; $P=0.986$). aFI correlated significantly with PI, PT and PI-LL before (PI: $R=0.448$, $P<0.001$; PT: $R=0.456$, $P<0.001$; PI-LL: $R=0.371$, $P<0.001$) and after adjusting for age (PI: $R=0.232$; $P=0.003$; PT: $R=0.278$, $P<0.001$; PI-LL: $R=0.180$, $P=0.021$). aFI did not correlate with SS ($R=0.113$, $P=0.149$) and LL ($R=-0.009$, $P=0.907$).

Severity of LSS correlated significantly with PI, PT and PI-LL before (PI: $R=0.187$, $P=0.016$; PT: $R=0.294$, $P<0.001$; PI-LL: $R=0.242$, $P=0.002$) but not after adjusting for age (PI: $R=-0.023$, $P=0.713$; PT: $R=0.130$, $P=0.097$; PI-LL: $R=0.080$, $P=0.302$). Severity of LSS did not correlate with SS ($R=-0.078$, $P=0.321$) and LL ($R=-0.083$, $P=0.288$).

FI correlated significantly with severity of LSS at levels L1-L2 ($R=0.190$; $P=0.014$), L2-L3 ($R=0.239$, $P=0.002$), L3-L4 ($R=0.302$, $P<0.001$), L4-L5 ($R=0.231$, $P=0.003$), but not at L5-S1 ($R=0.094$, $P=0.229$). aFI correlated significantly with severity of LSS before ($R=0.349$, $P<0.001$) but not after adjusting for age ($R=0.114$; $P=0.147$).

Only severity of LSS correlated with BMI ($R=0.200$, $P=0.010$).

Discussion

With the aging population, degenerative lumbar spinal stenosis has become a common disease. Chronic LSS can affect the patient's gait and further affect sagittal spinopelvic alignment [5]. PI, one of the most important sagittal alignment parameters, is a morphological parameter that remains constant after maturity and reflects the relationship between the sacrum and iliac wings [19]. The definition of PI-LL mismatch has been regarded as the foundation of modern sagittal alignment research [20]. Until now, potential correlations between LSS and sagittal alignment have not been explored. LSS can result from a number of causes, such as the degeneration of disc and facet joint and hypertrophy of the ligamentum flavum [2]. Paraspinal muscles are a large and complex group of muscles that play an important role in low back pain [21]. These muscles degenerate with age [22]. Evidence for an association of paraspinal muscle degeneration such as fatty infiltration independent of age is currently lacking.

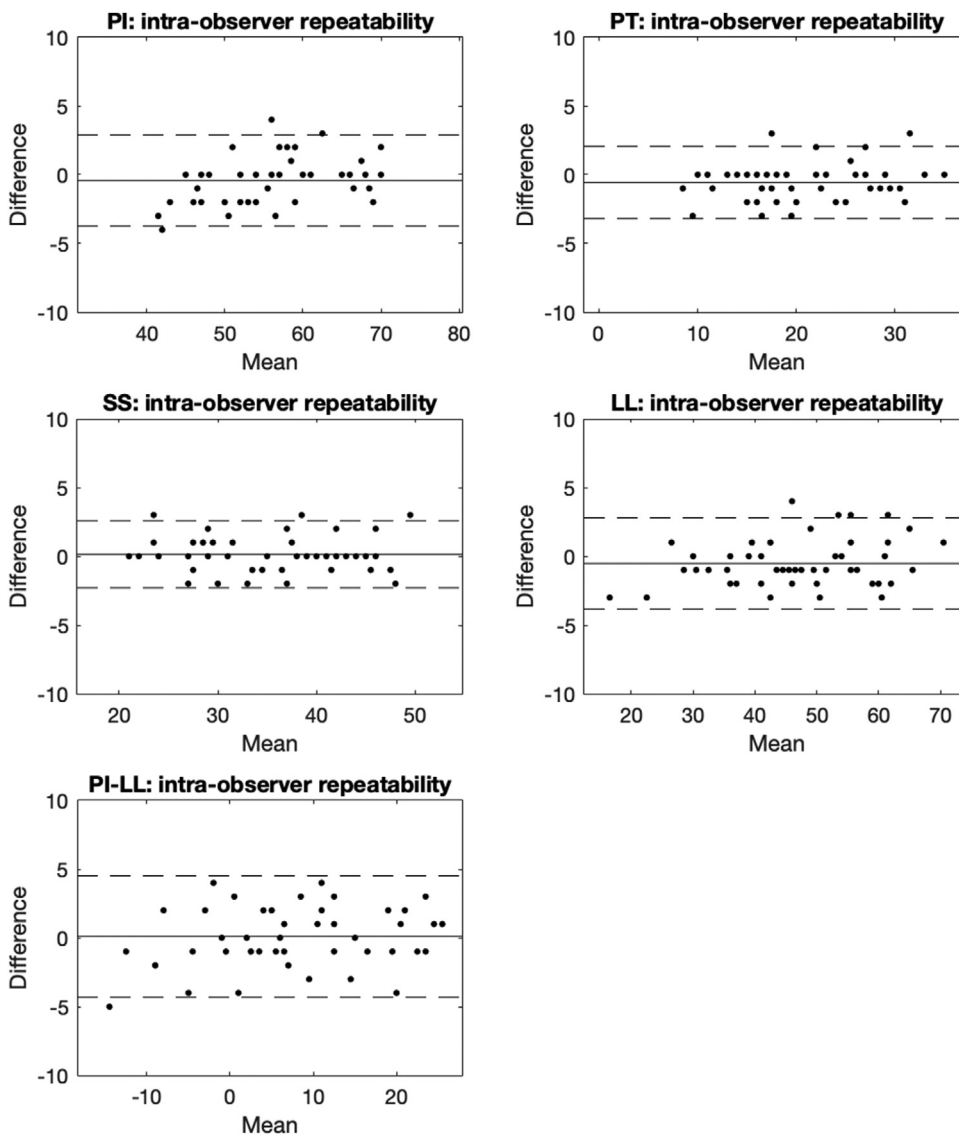


Fig. 4. Bland Altman plots of sagittal spinopelvic parameters for the intra-observer repeatability. In each graph the mean difference is indicated by a solid line and the 95% limits of agreement (1.96-fold standard deviation of difference) are indicated by dashed lines. PI—pelvic incidence; PT—pelvic tilt; SS—sacral slope; LL—lumbar lordosis; PI-LL—difference between PI and LL (pelvic incidence and lumbar lordosis mismatch).

We aimed to evaluate the association between fatty infiltration of paraspinal muscles, severity of LSS and sagittal pelvic alignment independent of age. It is important to note that muscle atrophy describes a decrease in muscle cross-sectional area while fatty infiltration describes the fatty tissue (contrary of lean muscle tissue) within a muscle relative to the muscle cross-sectional area. In our discussion, we refer to fatty infiltration or muscle atrophy according to the terminology used by the respective literature. In our study, fatty infiltration of paraspinal muscles but not severity of LSS correlated with PI and PI-LL and fatty infiltration of paraspinal muscles did not correlate with severity of LSS. Although all of these parameters change with age, the correlations among these parameters were independent of age. These results suggest that fatty infiltration of paraspinal muscles is associated with sagittal spinopelvic alignment that does not appear to be associated with the natural aging process. These results have important implications for the clinical assessment of patients with LSS.

Age and spinopelvic alignment

In our study, PI, PT and PI-LL correlated with age. PI, one of the most important sagittal spinopelvic parameters, is a morphological parameter that remains constant after maturity, reflects the relationship between the sacrum and iliac wings and determines the ideal sacral orientation

and ideal lumbar lordosis [19]. A high PI has been identified as one of the causative factors in the development and progression of spondylolisthesis and is assessed when evaluating and treating spondylolisthesis [23]. PI increases in adolescence after the age of 10 years and remains stable after reaching its maximum value in adulthood [24]. Legaye et al. [19] demonstrated a strong correlation between increasing PI and the age of subjects over 60 years. In addition, Bao et al. and Place et al. also observed greater PI in older patients with degenerative spinal diseases due to the increase in L5-S1 moment [25,26]. Hence, our result of an association between PI and age is consistent with previous studies [25].

PI-LL is a parameter that combines spine and pelvis alignment and is also of great value for evaluating sagittal alignment. PI-LL has been reported to be a key factor impacting disability and health-related quality of life scores in case of a mismatch of more than 10° [20,27]. The positive correlation between PI-LL and age indicates that older patients have a higher risk of PI-LL mismatch probably because aging of the spine is a kyphosing process caused by a progressive loss of disc height and joint degeneration [28].

Fatty infiltration of paraspinal muscles and spinopelvic alignment

Fatty infiltration of paraspinal muscles correlated with PI, PT and PI-LL independently of age. Jun et al. [12] found that fatty degeneration

correlates with PT, LL and PI-LL but these authors did not account for the effect of age. Our study confirmed these results: fatty infiltration of paraspinal muscles correlated positively with PI-LL. That means patients with greater fatty infiltration had greater sagittal spinopelvic alignment mismatch. This association appears to be specific to patients with degenerative spinal deformity as it is not present in asymptomatic adult persons [29,30]. Because forces exerted by paraspinal muscles are necessary for maintaining an upright posture in patients with LSS one would expect that patients with loss of lordosis need stronger muscles to maintain an upright position. A previous study [5] suggested that there might be a compensation mechanism in the course of the disease eventually leading to muscle atrophy. In our study, the lack of association between fatty infiltration of paraspinal muscles and LL suggests that patients may have compensatory posterior pelvic rotation (retroversion) that reduces the forces exerted by paraspinal muscles and eventually leads to fatty infiltration, thus influencing the sagittal balance in a vicious cycle resulting in progressive spine degeneration at the intervertebral disc and facet joints.

Muscle atrophy can occur for a number of reasons, including aging, denervation, or disuse [22]. Fatty infiltration may cause the impairment of muscular contractility which leads to the loss of muscle function [31]. The muscular system plays a critical role in maintaining postural balance, and the paraspinal muscles are important for lumbar spine stability. Muscle atrophy and fatty infiltration have been associated with degenerative diseases of spine presumably aggravating spinal deformity [32].

Xia et al. reported a significant correlation between relative cross-sectional area (functional muscle relative to the area of vertebral body) of the erector spinae muscle (normalized to body cross-sectional area) at the L3-4 level and PI and between relative cross-sectional area of the multifidus muscle and LL but not between relative cross-sectional area of the psoas and multifidus muscles and PI and LL [33]. The correlations reported by Xia et al. [33] and observed in our cross-sectional study do not allow to elucidate a causal relationship between muscle atrophy and spinopelvic alignment. It is possible that age associated fatty infiltration leads to accelerated spinal degeneration or that spinal degeneration leads to fatty infiltration because of, for instance, increasing disuse with disease progression.

Severity of lumbar spinal stenosis and spinopelvic alignment

Severity of LSS correlated with PI, PT and PI-LL only before adjusting for age which indicates that the correlations were dependent on age. While several studies [27,34] on sagittal malalignment have focused on patients with adult spinal deformity, there is currently little evidence on sagittal malalignment in patients with LSS. PI was found not to differ between patients with LSS and the normal population [35]. Buckland et al. [6] reported that foraminal stenosis severity was associated with greater PI-LL and PT. In contrast to the study by Buckland et al. [6], our results did not show a correlation between severity of LSS and PI or PT. We believe that the lack of age-adjustment in their study may explain this discordance because all of these parameters are associated with age.

In our study, LL was not associated with severity of LSS. In patients with chronic LSS, forward bending is often "used" with the aim of expanding the volume of the central vertebral canal to relieve the symptoms, which also theoretically affects LL [6]. This position correspondingly causes compensatory posterior pelvic rotation (retroversion), which increases PT and decreases SS [6]. In our study, the severity of LSS was not associated with these spinopelvic alignment parameters. It is possible that other factors such as duration of symptoms or compensation mechanism of knee flexion (not considered in our study) may affect this relationship. Based on our results, severity of LSS is not associated with sagittal alignment parameters. We still believe that spine surgeons should pay attention to the sagittal alignment given its well-

known correlation to quality of life or mechanical failure after surgery [20].

Severity of lumbar spinal stenosis and fatty infiltration of paraspinal muscles

Fatty infiltration of paraspinal muscles correlated with severity of LSS only before adjusting for age indicating that the correlation was dependent on age. The correlation of overall fatty infiltration and highest severity of stenosis was stronger than the correlation between these two parameters on each level. LSS is caused by a variety of factors, such as thickened ligament, degenerative arthritis and degenerative disc disease [2]. Muscle atrophy has been reported in patients with disc herniation and chronic low back pain [35]. Very few studies evaluated muscle atrophy in patients with LSS and the conclusions were controversial. For instance, Yarjanian et al. [3] reported greater muscle atrophy in symptomatic LSS compared with low back pain alone. Fortin et al. [36] found an association between greater multifidus muscle atrophy and functional status in LSS patients. In contrast, another study reported a negative association between fatty infiltration of paraspinal muscles and severity of LSS [5].

In our study, we found no association between fatty infiltration of paraspinal muscles and severity of LSS independent of age. Consistent with Kenichi et al. [37], we found that the severity of LSS correlated with BMI. They found that people with a higher BMI had a kyphotic and forward bended position and less spinal flexibility. BMI is calculated based on body weight and does not reflect body fat fraction. The correlation between severity of LSS and BMI may be due to the presumably greater load on the spine in a heavier person, which may lead LSS. In our study fatty infiltration of paraspinal muscles was not associated with BMI suggesting that the presence of obesity does not directly imply a higher percentage of fatty infiltration in paraspinal muscles.

Overall, the association of fatty infiltration of paraspinal muscles with spinopelvic parameters independent of age and the lacking association between fatty infiltration of paraspinal muscles and severity of LSS and between severity of LSS and spinopelvic parameters after adjusting for age suggest that fatty infiltration of paraspinal muscles plays an important role in LSS. In our study, we only assessed the severity of LSS radiologically, and clinical parameters such as pain or disease related disability were not investigated. While it is feasible that fatty infiltration of paraspinal muscles is an important aspect of the clinical manifestation, further research is needed to elucidate this relationship in LSS. Nonetheless, our results suggest that fatty infiltration of paraspinal muscles should be considered in the clinical evaluation of patients with LSS to gain a comprehensive understanding of the anatomical and physiological status of each patient necessary for clinical decision making. Moreover, our results emphasize the importance of assessing fatty infiltration of paraspinal muscles and symptoms in patients with LSS in research settings to further elucidate the etiology of this disease.

The large sample size and single center setting with the same diagnostic algorithm is a major strength of this study. In this study, we assessed only radiographic indicators, and data on clinical parameters such as pain or disease related disability were not available hence precluding an interpretation of the observed association with regards to symptoms. Although the Goutallier classification of fatty infiltration seems reliable, there are difficulties in the actual measurement because distinguishing between any two stages of fatty infiltration is sometimes difficult. Moreover, because the Goutallier classification is a qualitative scale, it is presumably less precise and reliable than quantitative ways of measuring muscle morphology such as cross-sectional area. Nonetheless, the results reported here are relevant because the Goutallier classification is a routine assessment in clinical settings. Despite of these limitations, this study clearly revealed the association among fatty infiltration of paraspinal muscles, severity of LSS and sagittal spinopelvic alignment.

Conclusions

The correlation of aFI with sagittal spinopelvic parameters indicates that there might be a relationship between muscle characteristics and the sagittal alignment. Sagittal spinopelvic parameters and fatty infiltration of paraspinal muscles are not associated with radiological severity of LSS. Whether they are associated with clinical manifestation of LSS remains to be investigated.

Declaration of Competing Interest

None.

Acknowledgements

This study was funded by the Department of Spinal Surgery of the University Hospital Basel, Switzerland and the University Library of University of Basel, Switzerland. The support provided by China Scholarship Council (CSC) during a visit of Y. Zhang to the University of Basel is acknowledged (No. 201906190229)

Supplementary materials

Supplementary material associated with this article can be found, in the online version, at [doi:10.1016/j.nxnsj.2021.100054](https://doi.org/10.1016/j.nxnsj.2021.100054).

References

- Steurer J, Nydegger A, Held U, et al. LumbSten: the lumbar spinal stenosis outcome study. *BMC Musculoskelet Disord* 2010;11:254.
- Otani K, Kikuchi S, Yabuki S, et al. Lumbar spinal stenosis has a negative impact on quality of life compared with other comorbidities: an epidemiological cross-sectional study of 1862 community-dwelling individuals. *Sci World J* 2013;2013:590652.
- Yarjanian JA, Fetzer A, Yamakawa KS, Tong HC, Smuck M, Haig A. Correlation of paraspinal atrophy and denervation in back pain and spinal stenosis relative to asymptomatic controls. *PM R* 2013;5(1):39–44.
- Chen YY, Pao JL, Liaw CK, Hsu WL, Yang RS. Image changes of paraspinal muscles and clinical correlations in patients with unilateral lumbar spinal stenosis. *Eur Spine J* 2014;23(5):999–1006.
- Bumann H, Nuesch C, Loske S, et al. Severity of degenerative lumbar spinal stenosis affects pelvic rigidity during walking. *Spine J* 2020;20(1):112–20.
- Buckland AJ, Ramchandran S, Day L, et al. Radiological lumbar stenosis severity predicts worsening sagittal malalignment on full-body standing stereoradiographs. *Spine J* 2017;17(11):1601–10.
- Duval-Beaupere G, Schmidt C, Cosson P. A Barycentremetric study of the sagittal shape of spine and pelvis: the conditions required for an economic standing position. *Ann Biomed Eng* 1992;20(4):451–62.
- Zarate-Kalfopulos B, Reyes-Tarrago F, Navarro-Aceves LA, et al. Characteristics of spinopelvic sagittal alignment in lumbar degenerative disease. *World Neurosurg* 2019;126:e417–ee21.
- Legaye J. The femoro-sacral posterior angle: an anatomical sagittal pelvic parameter usable with dome-shaped sacrum. *Eur Spine J* 2007;16(2):219–25.
- Yoshihara K, Shirai Y, Nakayama Y, Uesaka S. Histochemical changes in the multifidus muscle in patients with lumbar intervertebral disc herniation. *Spine (Phila Pa 1976)* 2001;26(6):622–6.
- Bushell GR, Ghosh P, Taylor TK. Collagen defect in idiopathic scoliosis. *Lancet* 1978;2(8080):94–5.
- Jun HS, Kim JH, Ahn JH, et al. The effect of lumbar spinal muscle on spinal sagittal alignment: evaluating muscle quantity and quality. *Neurosurgery* 2016;79(6):847–55.
- Masaki M, Ikezoe T, Fukumoto Y, et al. Association of sagittal spinal alignment with thickness and echo intensity of lumbar back muscles in middle-aged and elderly women. *Arch Gerontol Geriatr* 2015;61(2):197–201.
- Goutallier D, Postel JM, Bernageau J, Lavau L, Voisin MC. Fatty muscle degeneration in cuff ruptures. Pre- and postoperative evaluation by CT scan. *Clin Orthop Relat Res* 1994;304:78–83.
- Schizas C, Theumann N, Burn A, et al. Qualitative grading of severity of lumbar spinal stenosis based on the morphology of the dural sac on magnetic resonance images. *Spine (Phila Pa 1976)* 2010;35(21):1919–24.
- Celestre PC, Dimar JR 2nd, Glassman SD. Spinopelvic parameters: lumbar lordosis, pelvic incidence, pelvic tilt, and sacral slope: what does a spine surgeon need to know to plan a lumbar deformity correction? *Neurosurg Clin N Am* 2018;29(3):323–9.
- Kalichman L, Carmeli E, Been E. The association between imaging parameters of the paraspinal muscles, spinal degeneration, and low back pain. *Biomed Res Int* 2017;2017:2562957.
- Hayden AM, Hayes AM, Brechbuhler JL, Israel H, Place HM. The effect of pelvic motion on spinopelvic parameters. *Spine J* 2018;18(1):173–8.
- Boulay C, Bollini G, Legaye J, et al. Pelvic incidence: a predictive factor for three-dimensional acetabular orientation—a preliminary study. *Anat Res Int* 2014;2014:594650.
- Schwab FJ, Blondel B, Bess S, et al. Radiographical spinopelvic parameters and disability in the setting of adult spinal deformity: a prospective multicenter analysis. *Spine (Phila Pa 1976)* 2013;38(13):E803–12.
- Ranger TA, Cicuttini FM, Jensen TS, et al. Are the size and composition of the paraspinal muscles associated with low back pain? A systematic review. *Spine J* 2017;17(11):1729–48.
- Urrutia J, Besa P, Lobos D, et al. Lumbar paraspinal muscle fat infiltration is independently associated with sex, age, and inter-vertebral disc degeneration in symptomatic patients. *Skeletal Radiol* 2018;47(7):955–61.
- Min WK, Lee CH. Comparison and correlation of pelvic parameters between low-grade and high-grade spondylolisthesis. *J Spinal Disord Tech* 2014;27(3):162–5.
- Mac-Thiong JM, Berthodnaud E, Dimar JR 2nd, Betz RR, Labelle H. Sagittal alignment of the spine and pelvis during growth. *Spine (Phila Pa 1976)* 2004;29(15):1642–7.
- Bao H, Liabaud B, Varghese J, et al. Lumbosacral stress and age may contribute to increased pelvic incidence: an analysis of 1625 adults. *Eur Spine J* 2018;27(2):482–8.
- Place HM, Hayes AM, Huebner SB, Hayden AM, Israel H, Brechbuhler JL. Pelvic incidence: a fixed value or can you change it? *Spine J* 2017;17(10):1565–9.
- Schwab F, Ungar B, Blondel B, et al. Scoliosis research society-Schwab adult spinal deformity classification: a validation study. *Spine (Phila Pa 1976)* 2012;37(12):1077–82.
- Le Huec JC, Thompson W, Mohsinaly Y, Barrey C, Faundez A. Sagittal balance of the spine. *Eur Spine J* 2019;28(9):1889–905.
- Menezes-Reis R, Bonugli GP, Salmon CEG, Mazoroski D, Herrero C, Nogueira-Barbosa MH. Relationship of spinal alignment with muscular volume and fat infiltration of lumbar trunk muscles. *PLoS One* 2018;13(7):e0200198.
- Lee JC, Cha JG, Kim Y, Kim YI, Shin BJ. Quantitative analysis of back muscle degeneration in the patients with the degenerative lumbar flat back using a digital image analysis: comparison with the normal controls. *Spine (Phila Pa 1976)* 2008;33(3):318–25.
- Hamrick MW, McGee-Lawrence ME, Frechette DM. Fatty infiltration of skeletal muscle: mechanisms and comparisons with bone marrow adiposity. *Front Endocrinol (Lausanne)* 2016;7:69.
- Hides JA, Belavy DL, Stanton W, et al. Magnetic resonance imaging assessment of trunk muscles during prolonged bed rest. *Spine (Phila Pa 1976)* 2007;32(15):1687–92.
- Xia W, Fu H, Zhu Z, et al. Association between back muscle degeneration and spinal-pelvic parameters in patients with degenerative spinal kyphosis. *BMC Musculoskelet Disord* 2019;20(1):454.
- Iyer S, Sheha E, Fu MC, et al. Sagittal spinal alignment in adult spinal deformity: an overview of current concepts and a critical analysis review. *JBJS Rev* 2018;6(5):e2.
- Lim JK, Kim SM. Difference of sagittal spinopelvic alignments between degenerative spondylolisthesis and isthmic spondylolisthesis. *J Korean Neurosurg Soc* 2013;53(2):96–101.
- Fortin M, Lazary A, Varga PP, Battie MC. Association between paraspinal muscle morphology, clinical symptoms and functional status in patients with lumbar spinal stenosis. *Eur Spine J* 2017;26(10):2543–51.
- Hirano K, Imagama S, Hasegawa Y, Muramoto A, Ishiguro N. Impact of spinal imbalance and BMI on lumbar spinal canal stenosis determined by a diagnostic support tool: cohort study in communityliving people. *Arch Orthop Trauma Surg* 2013;133(11):1477–82.